

A recurrent mutation in the BMP type I receptor ACVR1 causes inherited and sporadic fibrodysplasia ossificans progressiva

Eileen M Shore¹⁻³, Meiqi Xu^{1,2}, George J Feldman^{1,2}, David A Fenstermacher⁴⁻⁶, The FOP International Research Consortium, Matthew A Brown⁷ & Frederick S Kaplan^{1,2,8}

Fibrodysplasia ossificans progressiva (FOP) is a rare autosomal dominant disorder of skeletal malformations and progressive extraskeletal ossification. We mapped FOP to chromosome 2q23-24 by linkage analysis and identified an identical heterozygous mutation (617G→A; R206H) in the glycine-serine (GS) activation domain of ACVR1, a BMP type I receptor, in all affected individuals examined. Protein modeling predicts destabilization of the GS domain, consistent with constitutive activation of ACVR1 as the underlying cause of the ectopic chondrogenesis, osteogenesis and joint fusions seen in FOP.

The formation of bone where it is neither needed nor wanted can lead to devastating consequences. FOP (OMIM 135100) is the most severe and disabling disorder of extraskeletal (heterotopic) ossification in humans¹. Heterotopic ossification in FOP begins in childhood and can be induced by trauma or may occur without warning. Bone formation is episodic and progressive, leading to extra-articular ankylosis of all major joints of the axial and appendicular skeleton, rendering movement impossible (Fig. 1a and Supplementary Note online).

The severe disability of FOP results in low reproductive fitness, and few examples of inheritance are known. When observed, genetic transmission is autosomal dominant and can be inherited from either mothers or fathers². In an initial genome-wide linkage analysis³, FOP was linked to a 36-cM region at chromosome 4q27-31; however, subsequent DNA sequence analysis of candidate genes in this region did not identify any mutations. With the discovery of additional pedigrees, we conducted a more conservative genome-wide linkage analysis using a subset of five families with the most stringent and unambiguous features of FOP (congenital malformation of the great toes and progressive heterotopic ossification in characteristic anatomic

patterns; Fig. 1a,b) in all affected family members (Supplementary Note and Supplementary Methods online). This approach excluded the 4q27-31 region and identified linkage of FOP to 2q23-24 in the region flanked by markers D2S1399 and D2S1238 (Fig. 1c). Using SNP genotyping, we fine-mapped the linkage region between rs1020088 (150,654,341 bp) and D2S1238 (174,505,230 bp). The multipoint lod score was 2.3 at $\theta = 0$ (Supplementary Fig. 1 online). No other genomic region showed consistent linkage in all five families. This genetic interval (Fig. 2a and Supplementary Note online) includes the activin A type I receptor gene (*ACVR1*; OMIM 102576; also known as *Alk2* or *ActRIA*), a receptor for bone morphogenetic protein (BMP)⁴. *ACVR1* is expressed in many tissues including skeletal muscle and chondrocytes^{5,6}. Constitutive activation of *ACVR1* induces alkaline phosphatase activity in C2C12 cells, upregulates *BMP4*, downregulates BMP antagonists, expands cartilage elements, induces ectopic chondrogenesis and stimulates joint fusions^{5,6}. *ACVR1* is therefore a strong candidate gene for FOP, which is associated with similar clinical findings and dysregulation of the BMP signaling pathway^{1,7-10}.

DNA sequence analysis of all *ACVR1* protein-coding exons and splice junctions (Supplementary Note and Supplementary Table 1 online) demonstrated the presence of an identical heterozygous single-nucleotide change at cDNA position 617 (617G→A) in all examined familial and sporadic individuals with FOP (Fig. 2b). We found this mutation in all affected members of seven families, including all five families used for linkage analysis (Fig. 1c). Investigation of sporadic cases of FOP with unambiguous clinical features showed the presence of the identical *de novo* mutation in 32 of 32 cases. The examined individuals with an *ACVR1* 617G→A mutation included an individual with a previously reported, but unverifiable, mutation in the gene encoding *Noggin*^{11,12}. In addition to direct DNA sequence analysis, we verified the G→A nucleotide change by differential restriction endonuclease digestion (Fig. 2c).

The 617G→A nucleotide mutation was not found in any of 159 unaffected individuals (112 unrelated controls and 47 clinically unaffected family members). Included among the unaffected family members that we examined were the parents of six individuals with sporadic FOP. Absence of the mutation in these parents as well as in unaffected members of the linkage pedigrees (Fig. 1c) support that this mutation is fully penetrant. The *ACVR1* 617G→A nucleotide variant is not reported in SNP databases (<http://www.ncbi.nlm.nih.gov/SNP>; http://www.ensembl.org/Homo_sapiens/gensnpview).

Sporadic cases of FOP have been reported in diverse geographic and ethnic groups, and we found *de novo ACVR1* 617G→A mutations

¹Center for Research in FOP and Related Disorders, ²Department of Orthopaedic Surgery, ³Department of Genetics, ⁴Department of Pathology and Laboratory Medicine, ⁵Abramson Cancer Center and ⁶Biomedical Informatics Facility, University of Pennsylvania School of Medicine, Philadelphia, Pennsylvania 19104, USA. ⁷Centre for Immunology and Cancer Research, Princess Alexandra Hospital, Ipswich Road, Woolloongabba, Queensland 4102, Australia. ⁸Department of Medicine, University of Pennsylvania School of Medicine, Philadelphia, Pennsylvania 19104, USA. Correspondence should be addressed to E.M.S. (shore@mail.med.upenn.edu) or F.S.K. (Frederick.Kaplan@uphs.upenn.edu).

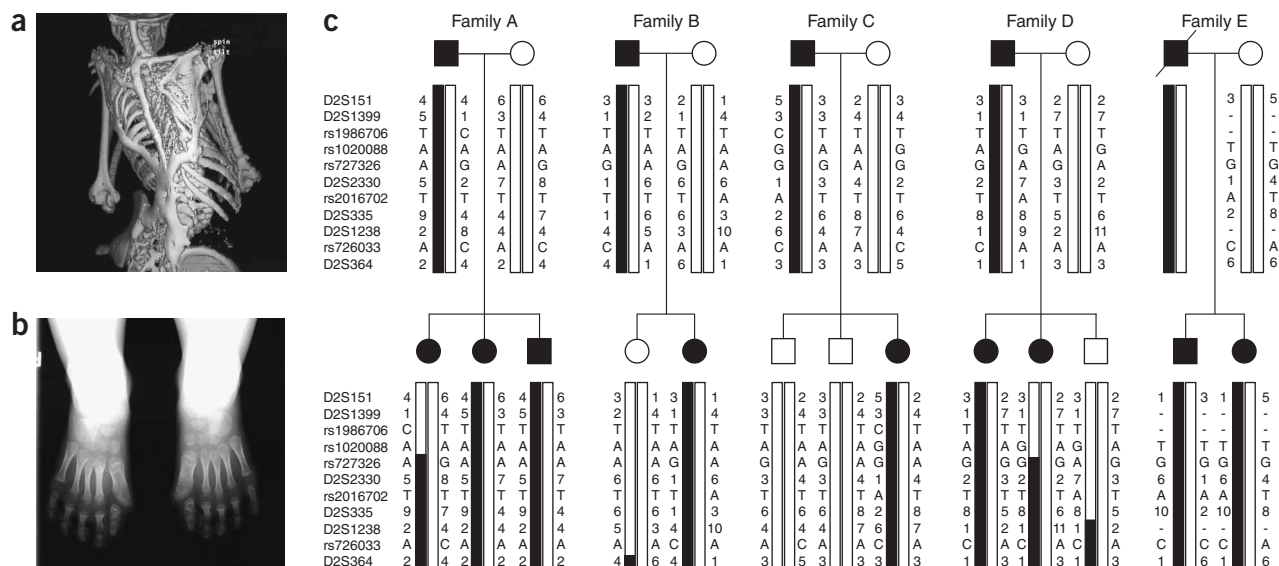


Figure 1 Characteristic clinical features of FOP and linkage mapping in five pedigrees. **(a)** Extensive heterotopic bone formation typical of FOP is seen by three-dimensional reconstructed computed tomography (CT) scan of the back of a 12-year-old child. **(b)** Anteroposterior radiograph of the feet of a 3-year-old child shows symmetrical great toe malformations. **(c)** Marker haplotypes on chromosome 2q23-24 that are linked to FOP are indicated by black bars. Marker positions were obtained from the University of California Santa Cruz Genome Browser. Microsatellite markers and SNPs are listed at left from centromere to telomere (top to bottom). Haplotypes were interpreted by minimizing recombinants. In each haplotype pair, paternal haplotypes are to the left and maternal to the right (see also **Supplementary Methods** online).

in all the populations we analyzed. The pedigrees we examined by linkage were of diverse ancestral origins (African-American, European American, European (UK), Korean and Native Brazilian), and haplotype analysis of markers in the linked region (**Fig. 1c**) did not demonstrate any evidence of a founder effect for the mutation.

Analysis of *ACVR1* mRNA expression by RT-PCR and sequencing showed that both mutant and normal mRNAs were expressed in FOP cells, suggesting that the mutation effects are not due to haploinsufficiency but are more likely due to altered protein function. Constitutive *ACVR1* expression in embryonic chick limbs induces expansion of chondrogenic anlage, suggesting that *ACVR1* signaling alters cell fate and induces undifferentiated mesenchyme to form cartilage⁶. Enhanced *ACVR1* activation in FOP is supported by our recent data showing increased expression of BMP transcriptional targets in FOP cells^{9,10}.

The *ACVR1* 617G→A mutation causes an amino acid change in codon 206 (R206H; CGC→CAC). Comparison of *ACVR1* protein sequences shows that amino acid 206 is highly conserved among vertebrates (**Fig. 2d**) and is also highly conserved among human *ACVR1* family members (**Supplementary Fig. 2** online). Codon 206 is at the end of the highly conserved glycine-serine (GS) activation domain at the junction of the protein kinase domain (**Fig. 2a**). Activation of a BMP/TGFβ type I receptor serine-threonine kinase, and consequent signaling, requires phosphorylation at the GS domain by a BMP type II receptor.

To investigate the possible consequences of the R206H mutation, we used protein homology modeling to examine putative structural changes caused by this mutation. PredictProtein and CPHmodels (**Supplementary Methods** online) both predict a partial destabilization of the α-helix formed by *ACVR1* amino acids 198–206 (**Fig. 2e**). The R206H mutation forms a shorter side chain that alters the electrostatic potential compared with wild-type *ACVR1*, possibly

disrupting intramolecular interactions that stabilize *ACVR1* and/or altering interactions between the GS domain and other signaling pathway molecules (**Supplementary Note** online).

The GS domain is a critical site for binding and activation of R-Smad signaling proteins and is a binding site of FKBP12, an inhibitory protein that prevents leaky activation of the type I receptor in the absence of ligand¹³. One possibility is that FKBP12 interactions with the GS domain may be altered, leading to promiscuous *ACVR1* activity¹⁴. How R206H mutations in *ACVR1* specifically perturb BMP signaling in FOP is unknown but could involve dysregulation of BMP receptor oligomerization, internalization and/or activation of downstream signaling^{9,10,15}.

We identified the identical DNA sequence change in *ACVR1* in every individual with FOP we examined, with the exception of one multigenerational family with highly ambiguous disease features (**Supplementary Note** online). The FOP R206H *ACVR1* mutation is thus one of the most specific codons in the human genome to be associated with a disease phenotype.

The *ACVR1* R206H mutation is among a growing list of human disease-causing mutations in BMP receptor genes including *BMPRIA* (juvenile polyposis syndrome; OMIM 174900), *BMPRIIB* (brachydactyly type A2; OMIM 112600) and *BMPRII* (primary pulmonary hypertension; OMIM 178600), and it establishes a specific link between a catastrophic disorder of dysregulated osteogenesis and a highly conserved signaling pathway. Although *ACVR1* has previously been recognized as a BMP receptor, investigations of its functions in embryonic development and in regulating cell differentiation have been limited. Identification of a specific disease-causing mutation in *ACVR1* has critical diagnostic and therapeutic implications for FOP and identifies a new investigative focus for skeletal biology and regenerative medicine.

Note: Supplementary information is available on the Nature Genetics website.

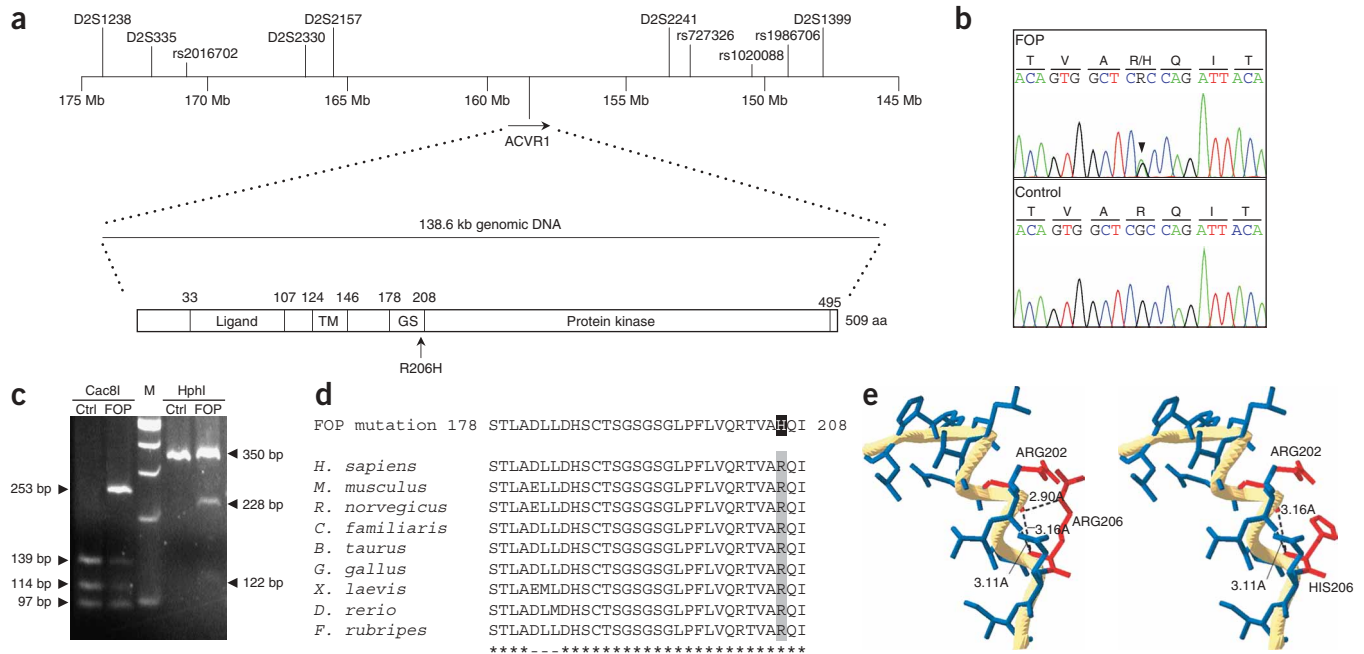


Figure 2 R206H mutations in *ACVR1* cause FOP. **(a)** The chromosome 2q FOP critical genomic region spans ~23.9 Mb between rs1020088 and D2S1238 and contains *ACVR1*. An arrow indicates the position of the R206H mutation in the glycine-serine (GS)-rich domain. **(b)** Direct DNA sequence analysis of *ACVR1* demonstrated the same heterozygous mutation (R206H; 617G→A) in all individuals with FOP we examined. Chromatograms are from a representative affected individual (top; FOP) and unaffected control (bottom). In the FOP sample, R = adenine or guanine; R/H = arginine or histidine. **(c)** The G→A mutation forms a new *HphI* site and eliminates a *Cac8I* site. The PCR product (350 bp) from the G allele (control; Ctrl) is digested by *Cac8I* to three bands (139, 114, and 97 bp), whereas the A allele produces two bands (253 and 97 bp). Samples from individuals with FOP are heterozygous for the two alleles. The PCR product not digested with *HphI* corresponds to the G allele (control); digested products (228 and 122 bp) correspond to the A allele (in FOP). **(d)** *ACVR1* codon 206 is highly conserved among species. ClustalW was used for multiple protein sequence alignment. **(e)** Homology model of wild-type *ACVR1* (left) predicts that the Arg206 side chain interacts with the α -helix backbone to stabilize the protein (dashed line). Homology model of the R206H mutant (right) predicts that the His206 side chain does not interact with the α -helix backbone (see also **Supplementary Methods** online).

ACKNOWLEDGMENTS

The members of the FOP International Research Consortium have been critical in identifying FOP multigenerational families and/or made important contributions to this collaborative effort. We thank the individuals and families with FOP providing tissue samples for these studies and for their courage and faith; J. Peeper and A. Cali for their inspiration and leadership of the international FOP community; many colleagues for discussions over the course of these investigations and many physicians worldwide who referred patients and helped in sending tissue samples. We acknowledge the contributions of R. Pignolo, University of Pennsylvania School of Medicine; M. Fardeau, Institut de Myologie, Hôpital de la Salpêtrière; D. Baldwin, University of Pennsylvania Microarray Core Facility; G. Abecasis, University of Michigan, for linkage data analysis advice; C. Street, University of Pennsylvania Biomedical Informatics Facility; University of Pennsylvania School of Medicine DNA Sequencing Facility and the University of Utah School of Medicine Genomics Core Facility. We thank V. Cheung for discussion of the manuscript, M. Liljeström for her observations and the people of Santa Maria and many other communities around the globe for their faith and generosity over many years. We also thank the many present and past members of our laboratory for their dedication and technical support, particularly those who have participated in candidate gene screening, especially A. Strong, H. Yang, and P. Chen. This work was supported by endowments from the Cali and Weldon families and their associates and friends, the Isaac and Rose Nassau Professorship of Orthopaedic Molecular Medicine, the Roemex and Grampian Fellowships, the Stephen Roach-Whitney Weldon Fellowship and grants from the International Fibrodysplasia Ossificans Progressiva Association (<http://www.ifopa.org>), Association Pierre-Yves, FOPe.v., University of Oxford FOP Research Fund, the Sarah Cameron Fund, and the US National Institutes of Health (NIH R01-AR41916).

AUTHORS' CONTRIBUTIONS

The FOP Consortium members are Tae-Joon Cho and In Ho Choi (Seoul National University Children's Hospital, Seoul, Korea), J. Michael Connor

(University of Glasgow School of Medicine, Glasgow, Scotland), Patricia Delai (Sao Paulo, Brazil), Martine LeMerrer (Hôpital Necker-Enfants Malades, Paris), Rolf Morhart (Klinikum Garmisch-Partenkirchen, Garmisch-Partenkirchen, Germany), John Rogers (The Royal Children's Hospital, Melbourne, Australia), Jon Andoni Urtizberea (European Neuromuscular Center, Baarn, The Netherlands), Roger Smith and James Triffitt (University of Oxford, Oxford) and David Glaser and Michael Zasloff (University of Pennsylvania School of Medicine, Philadelphia).

COMPETING INTERESTS STATEMENT

The authors declare competing financial interests (see the *Nature Genetics* website for details).

Published online at <http://www.nature.com/naturegenetics>

Reprints and permissions information is available online at <http://npg.nature.com/reprintsandpermissions/>

- Kaplan, F.S. *et al.* in *Connective Tissue and Its Heritable Disorders* (eds Royce, P. & Steinmann, B.) 827–840 (Wiley-Liss, New York, 2002).
- Shore, E.M. *et al.* *Clin. Rev. Bone Miner. Metab.* **3**, 201–204 (2005).
- Feldman, G. *et al.* *Am. J. Hum. Genet.* **66**, 128–135 (2000).
- Attisano, L. *et al.* *Cell* **75**, 671–680 (1993).
- Payne, T.L. *et al.* *Mech. Dev.* **100**, 275–289 (2001).
- Zhang, D. *et al.* *J. Bone Miner. Res.* **18**, 1593–1604 (2003).
- Shafritz, A.B. *et al.* *N. Engl. J. Med.* **335**, 555–561 (1996).
- Ahn, J. *et al.* *J. Bone Joint Surg. Am.* **85-A**, 667–674 (2003).
- Serrano de la Peña, L. *et al.* *J. Bone Miner. Res.* **20**, 1168–1176 (2005).
- Fiori, J.L. *et al.* *J. Bone Miner. Res.* published online 27 February 2006 (doi:10.1359/jbmr.060215).
- Xu, M. *et al.* *Clin. Genet.* **58**, 291–298 (2000).
- Xu, M.Q. *et al.* *Am. J. Med. Genet.* **109**, 161 (2002).
- Huse, M. *et al.* *Mol. Cell* **8**, 671–682 (2001).
- Wang, T. *et al.* *Cell* **86**, 435–444 (1996).
- Massagué, J. *et al.* *Cell* **103**, 295–309 (2000).