



# The Modified V-Y Dorsal Metacarpal Flap for Repair of Syndactyly Without Skin Graft: Fifty Consecutive Cases

Vivian M. Hsu, BA, James M. Smartt, MD, and Benjamin Chang, MD, FACS

Division of Plastic Surgery, Department of Surgery, The Children's Hospital of Philadelphia, and University of Pennsylvania School of Medicine, Philadelphia, Pennsylvania

## BACKGROUND

- Syndactyly is a common congenital hand deformity, occurring with an incidence of 1 in every 2000 to 2500 births. The goal for syndactyly release is to create a functional hand while incurring the minimum amount of long-term morbidity. Specifically, this means creating a functional and aesthetically acceptable web commissure using the minimum number of procedures with a low rate of complications.
- The traditional method of repair over the last 60 years has involved the creation of interdigitating flaps via zigzag incisions with full thickness skin grafts (FTSGs) used to resurface remaining defects. Although this method of syndactyly repair has been used for decades, the use of FTSGs is time-consuming and often associated with suboptimal postoperative results, such as graft contraction, web creep, partial graft loss, hyperpigmentation, hair growth following puberty, and hypertrophic scarring.
- The V-Y dorsal metacarpal flap eliminates the need for FTSGs in most simple syndactyly repairs by advancing skin from the lax dorsal surface of the hand into the newly formed web space. This study is a retrospective review of the senior author's experience with the use of a modified V-Y dorsal metacarpal flap without skin grafts in the treatment of congenital syndactyly of the hand.

## MATERIALS AND METHODS

- A retrospective chart review of all patients who underwent syndactyly repair by the senior author between November 1998 and June 2007 was performed. All patients that underwent syndactyly repair without skin grafting during this time period were included in the study. Patients without available follow-up data also were included but were excluded in the statistical analysis of postoperative complications. Patients with other congenital hand abnormalities in addition to syndactyly, including hypoplasia, cleft hand, polydactyly, clinodactyly, and duplicated or missing phalanges were not excluded from the study. Exclusion criteria included: complex syndactyly, complicated syndactyly, and syndactyly of the first web space.
- Both inpatient and outpatient charts were reviewed. Variables collected included pertinent demographic data such as: patient age at the time of operation, sex, type and location of syndactyly, and the presence of any other congenital deformities.
- Specific outcomes that were investigated included details of the operative procedure: 1) operative times and 2) intraoperative complications such as neurovascular injury. Furthermore, the incidence of postoperative complications was recorded, specifically: 1) infection, 2) full or partial flap loss, 3) web creep, 4) flexion contractures, 5) hypertrophic scarring, 6) angulation deformity, 7) decreased range of motion, and 8) need for reoperation. To determine the average operative time, only cases in which a single simple syndactyly was performed were recorded. To measure the frequency of complications, the outcomes were quantified in two groups of syndactyly repair: 1) simple incomplete syndactyly and 2) simple complete syndactyly.

## SURGICAL TECHNIQUE

- The flap performed by the senior author is a modification of the V-Y dorsal metacarpal flap as described by MM Sherif. It is designed on the dorsum of the hand between the metacarpal heads of the involved fingers with the distal tip of the flap at the level of the proposed web space. The flap is hexagonal in shape with a 3:1 length-to-width ratio.
- Markings for the finger incisions are composed in a traditional zigzag fashion, creating triangular flaps with the mirror image incision marked on the palmar side to create interdigitating flaps. The incision is then continued as a straight line toward the palm 5 mm proximal to the depth of the proposed web space.
- After these markings are made, the arm is exsanguinated and a tourniquet inflated. The fingers are separated along the zigzag incisions. The full-thickness V-Y dorsal island flap is raised and the subcutaneous tissues dissected free to mobilize the flap distally. The deep soft tissues are maintained as a vascular pedicle between the metacarpal heads. The fat between the two proximal phalanges is excised while avoiding injury to the digital neurovascular bundles.
- The dorsal V-Y flap is advanced through the web space, and the distal tip is sutured to the palmar skin to create the volar aspect of the web. The triangular flaps are then wrapped around the newly separated fingers and sutured in place to completely close the skin along the sides of the two fingers. The dorsal wound is then closed in a V-Y fashion.

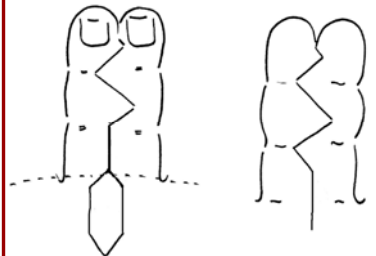


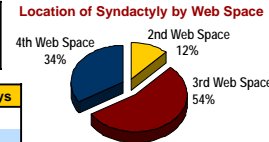
FIGURE 1. Illustration depicting the markings for incisions for the elevation of the modified dorsal metacarpal V-Y flap as used by the senior author.

## PATIENT DEMOGRAPHICS

Sex	Number of Patients
Male	27
Female	11

Syndactyly Type	Number of Syndactyls
Simple incomplete	42
Simple complete	8



## RESULTS

- At time of surgery, the patients ranged in age between 3 months and 17 years, with a median age of 12 months. From adequate data available for 47 repairs, the average duration of follow-up was 2.6 years with a range of 1 month to 8.5 years.
- The average size of the V-Y dorsal metacarpal flap was 7.6 x 23.5 mm with an average advancement of 9.9 mm (range: 4-11 mm width, 15-44 mm length, 5-15 mm advancement). The average surgical time for repair of a simple syndactyly using this flap was 69.4 minutes (range: 40-129 minutes). There were no intraoperative complications and no cases of neurovascular compromise. There were also no incidences of flap loss or ischemic injury. In all patients, the donor site of the dorsal flap healed with minimal scar formation.

## Postoperative Complications

Unsatisfactory postoperative results by syndactyly type (n=2, overall 4.3%)

Syndactyly Type	Number of Suboptimal Repairs	Postoperative Result
Simple incomplete (n=40)	1 (2.5%)	Angulation, reoperation
Simple complete (n=7)	1 (14.3%)	Web creep, reoperation

## CONCLUSIONS

- This is the largest clinical series of syndactyly repair without skin graft to date. The modified V-Y dorsal metacarpal flap obviates the need for skin grafting in the repair of simple syndactyly. Without the requirement of skin grafts, this technique eliminates graft complications and shortens operative time. With no intraoperative complications and significantly few late complications, this technically simple and reliable procedure improves upon previous approaches to the surgical reconstruction of simple syndactyls.
- However, skin grafts are still required for the repair of complex syndactyls, so we recommend the standard repair which leaves a less visible dorsal scar.

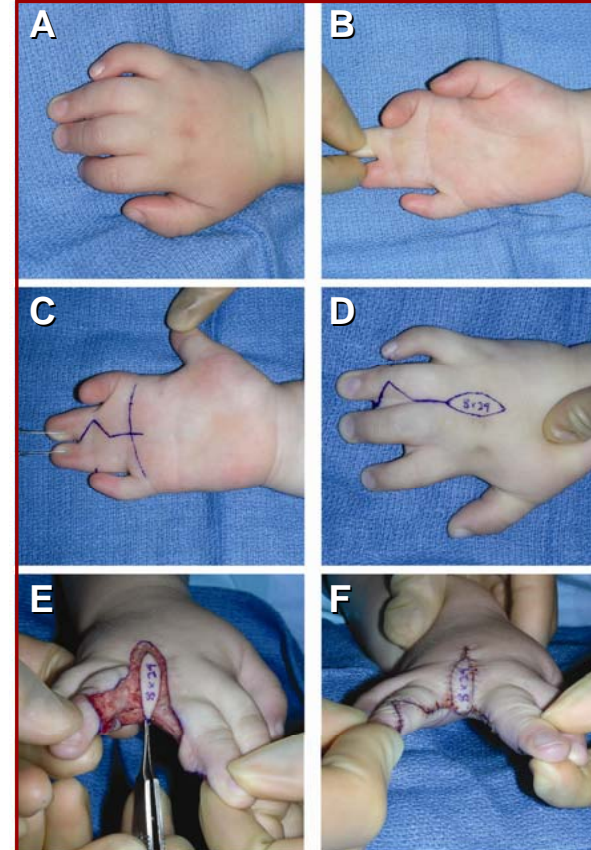


FIGURE 2. Surgical technique of the modified V-Y dorsal metacarpal flap for syndactyly repair.  
 A, B: Simple incomplete syndactyly of the third web space.  
 C, D: Preoperative markings.  
 E: The modified V-Y flap mobilized.  
 F: The flap advanced and inset.

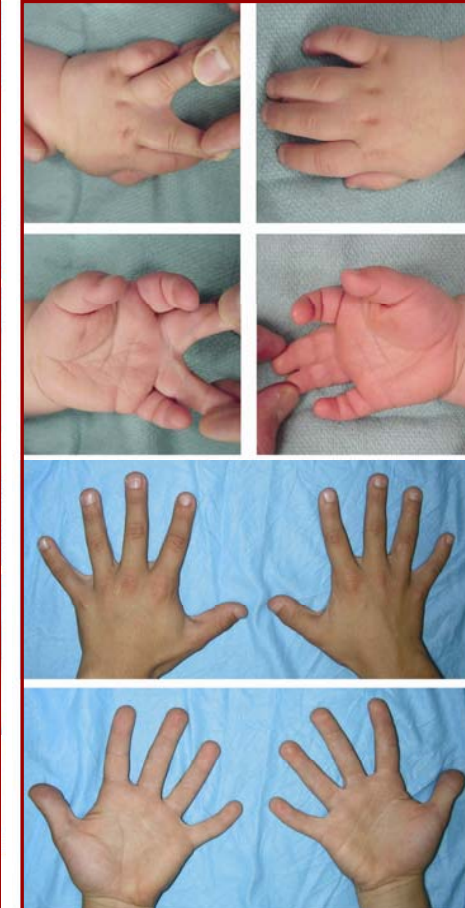

FIGURE 3. Preoperative photos of a patient with bilateral incomplete syndactyly of the third web space at 13 months of age.  
 Postoperative photos taken at 9.5 years of age.